

**PERKÜTAN NEFROLİTOTOMİDE
(PCNL) EĞİTİM MODELLERİ
&
3D PRINT**

Dr.Fatih Altunrende

Okmeydanı Eğitim ve Araştırma Hastanesi


PCNL

- Ürolojik cerrahi pratiğimizin büyük bir kısmını taş cerrahisi oluşturmaktadır.
- Perkütan nefrolitotomi uygulanabilirliği ve tatmin edici cerrahi sonuçlarıyla özellikle kompleks böbrek taşı tedavisinde ilk seçenekler arasında yer almaktadır.

Güner ND, 2010

PCNL - AMAÇ

- Taşsızlık
- Komplikasyon oranı (minor-major)
- Operasyon süresi
- Floroskopi süresi



PCNL-RENAL GİRİŞ

- En önemli aşama

- Uygun perkütan renal akses

YÜKSEK BAŞARI

- Uygun perkütan renal akses

2D GÖRÜNTÜ

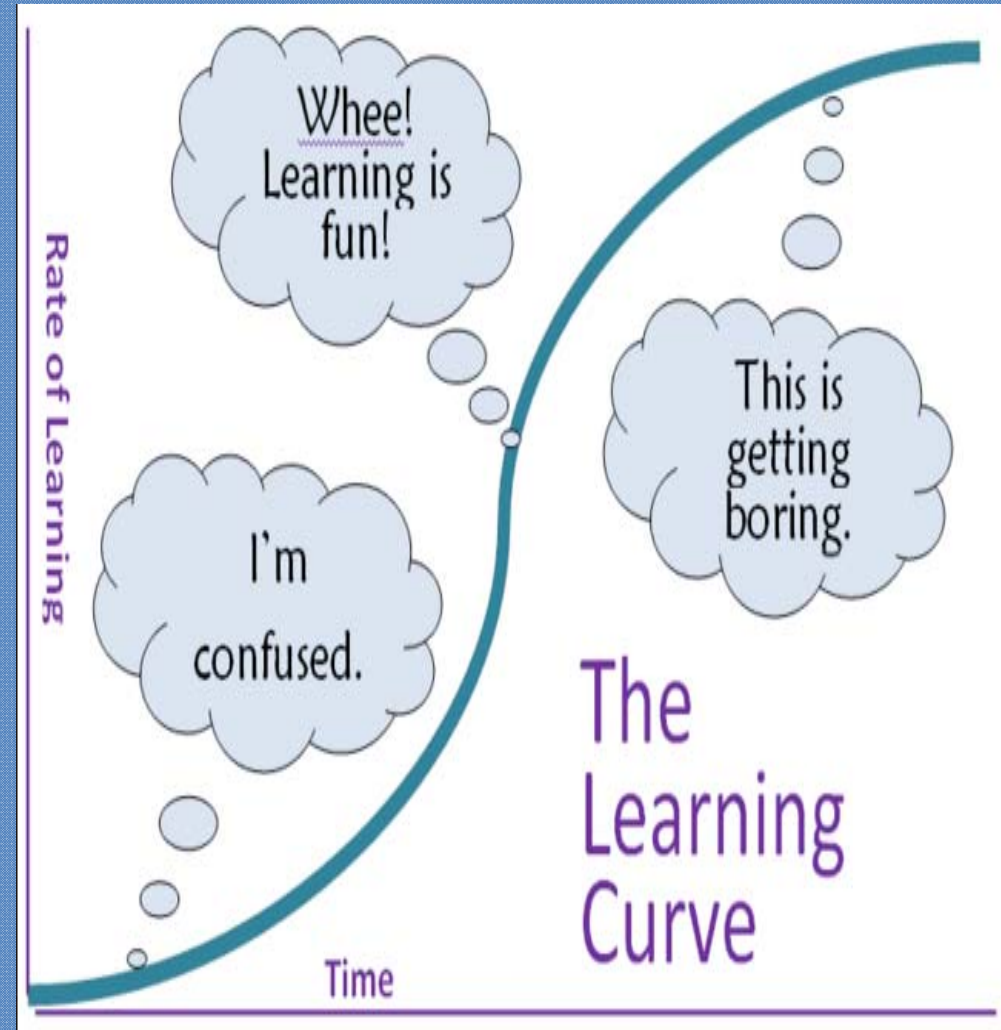
MENTAL 3D

YÜKSEK BAŞARI VE YÜKSEK KOMPLİKASYON

PCNL

- 24 yapılabirlik
- 60 yetkin
- >100 mükemmel

De la Rosette JJ, Eur Urol 2008
Tanriverdi O, Eur Urol, 2007
Allen D, J Endourol, 2005

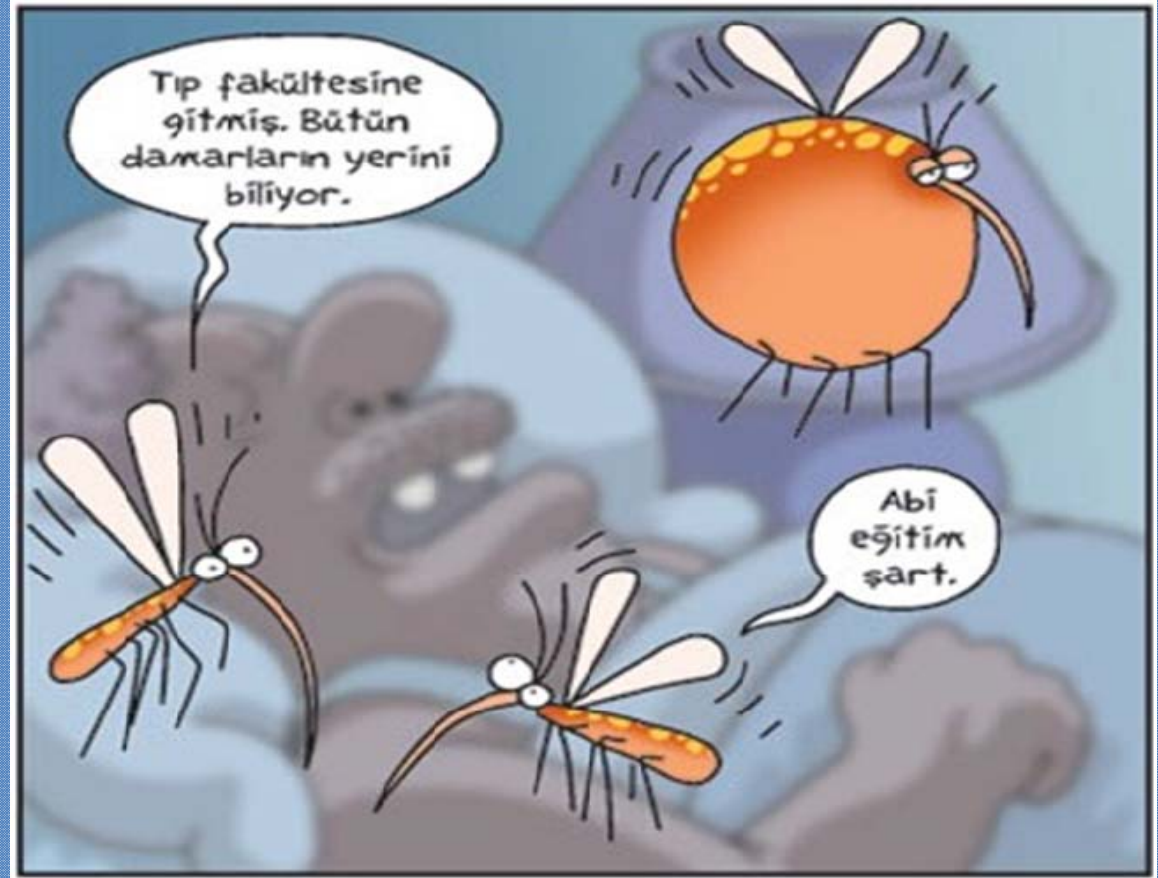





PCNL-EĐİTİM


- Teorik
- Grsel & iŐitsel
- Eđitmen eŐliđinde

3D PRINT !!!!!

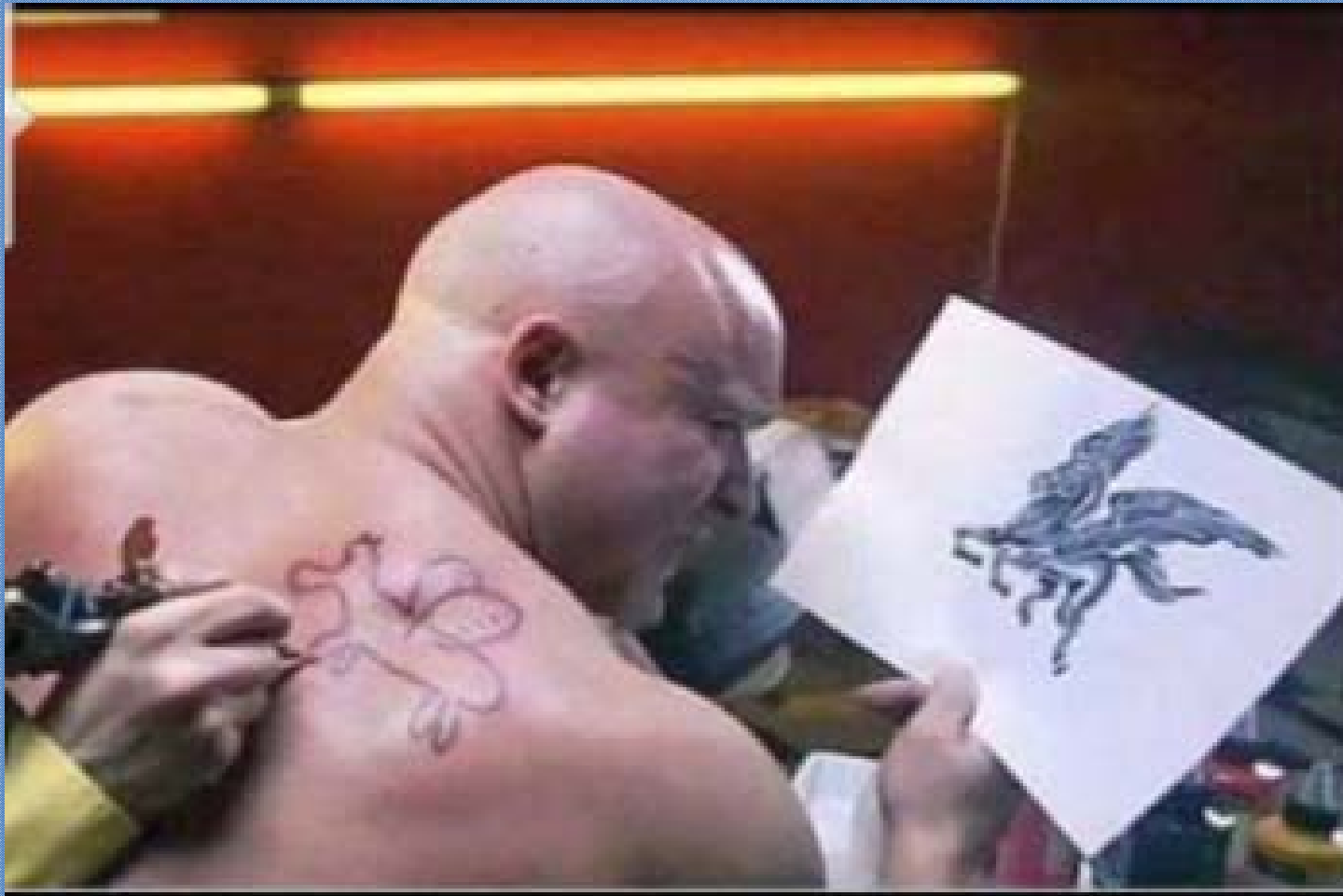TEORİK



EĐİTİM-GÖRSEL



TEORİK+GÖRSEL



EĞİTMEN-PRATİK



RESIDENCY TRAINING IN PERCUTANEOUS RENAL ACCESS: DOES IT AFFECT UROLOGICAL PRACTICE?

COURTNEY L. LEE, J. KYLE ANDERSON AND MANOJ MONGA^{*†}

- 1981-2001 yılları arasında üroloji asistanlığını tamamlayan 37 kişi arasında yapılan anket
- Asistanların %74'ünde PNL eğitimi (+)
- Bunların da %73'ü asistanlık sonrası PNL aksesi yapmada kendini yeterli görüyor
- Bu grup asistanlık döneminde **ortalama 21.2 ± 4.5 akses** yapmış

PCNL- EĞİTİM

Medline keywords

- Training
- Percutaneous surgery
- Renal calculi
- PCNL
- Virtual reality
- Simulators

PCNL- EĞİTİM

- Gerçeğine yakın
- Kolay ulaşılabilir
- Tekrarlı
- U

Hali hazırda yok!

PCNL -MODEL

WET LABORATORY (canlı hayvan modelleri)

DRY LABORATORY

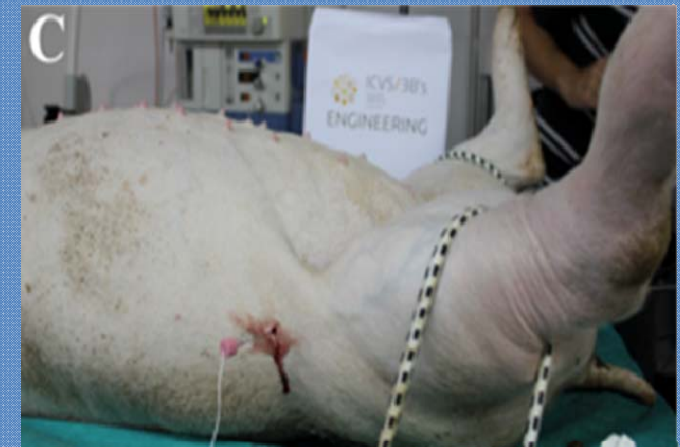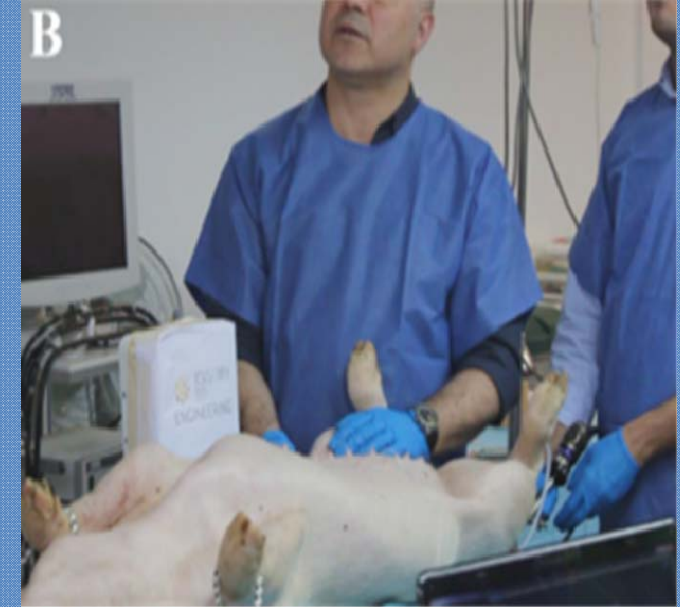VIRTUAL REALITY (VR) model

CANLI DOMUZ-AVANTAJ

- İnsan renal anatomisi uygunluk
- Böbrek hareketleri
- Duyu hissi
- Komplikasyon

CANLI DOMUZ -DEZAVANTAJ

- Organizasyon zor
- Perinefrik yağ dokusu çok az
- Böbrek oldukça mobil ve küçük
- Kaliks sayısı fazla
- Maliyet-Etik



Ex vivo hayvan modelleri-I

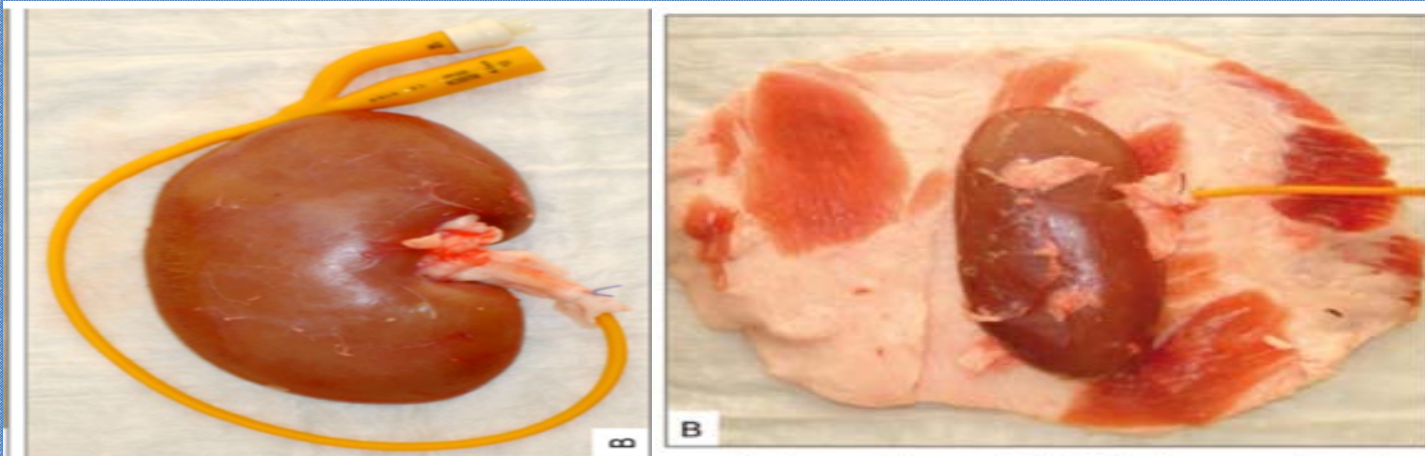
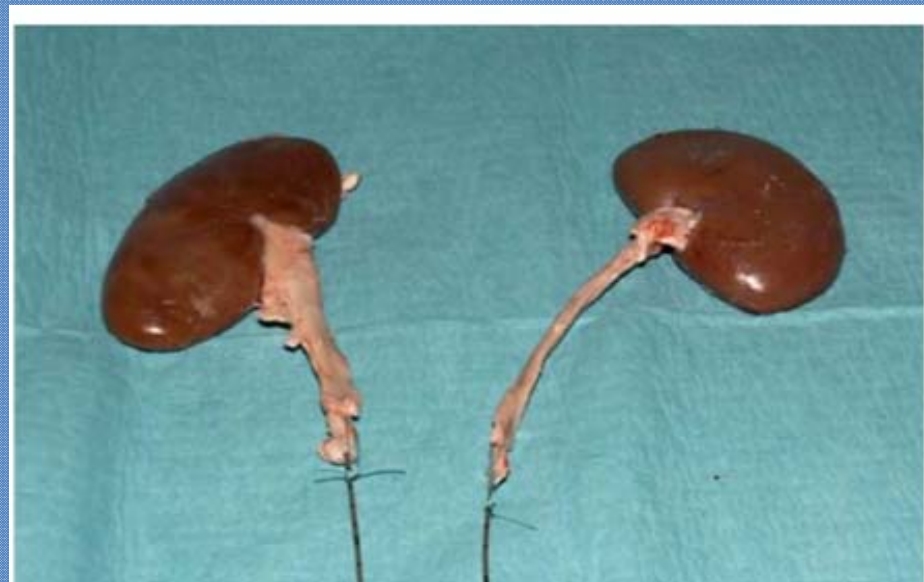

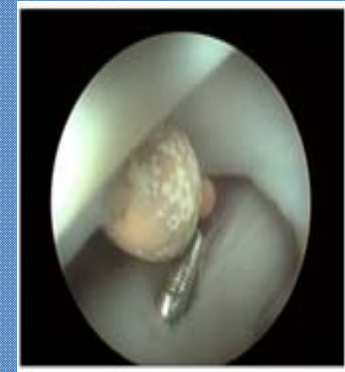Figure 1 - Freshly harvested porcine kidney (A) and full thickness skin flap used to cover the kidney (B).


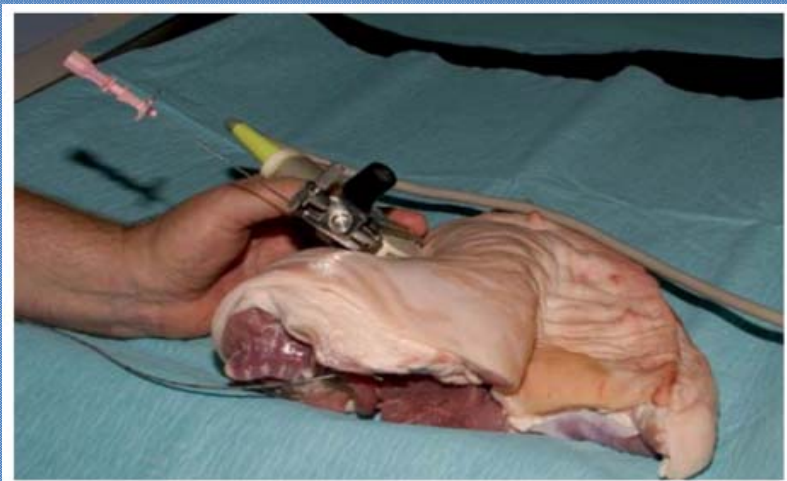
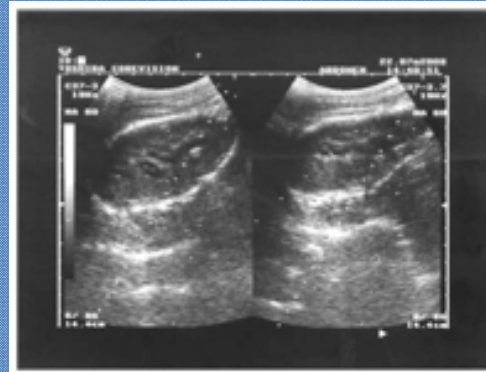
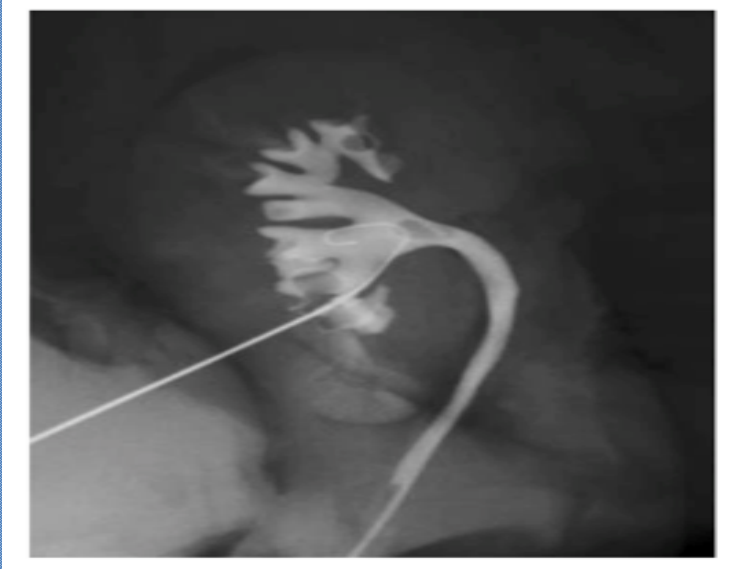


Figure 3 - Guide-wire for easy access to the renal pelvis (A) and wrapped organ model, closed by running sutures, in the plastic tray for subsequent training (B).

Ex vivo hayvan modelleri-II



Strohmaier WL, Urol Res, 2009

Ex vivo hayvan modelleri-III

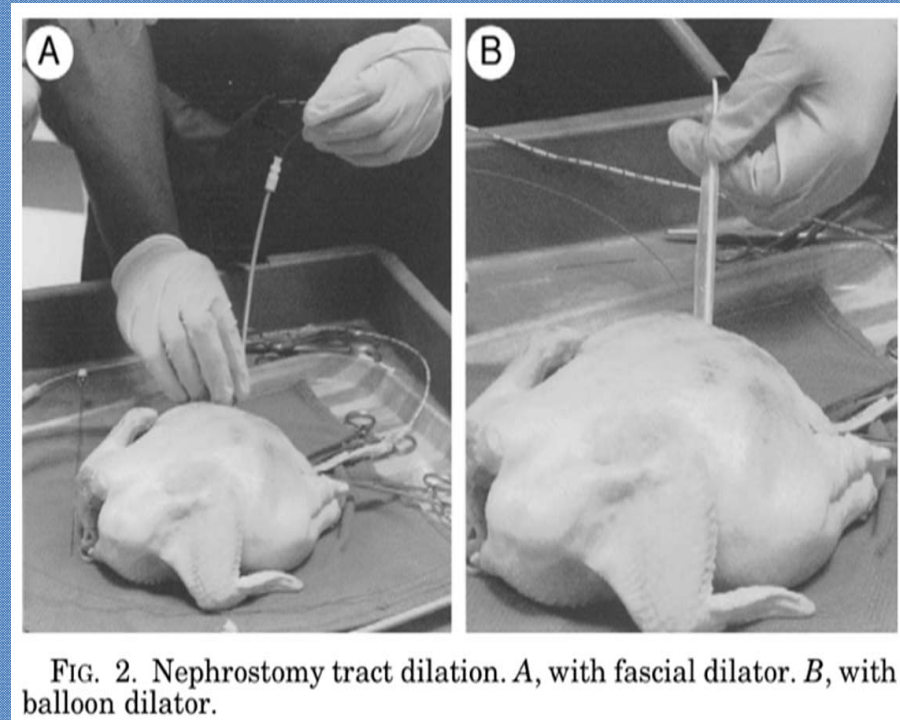
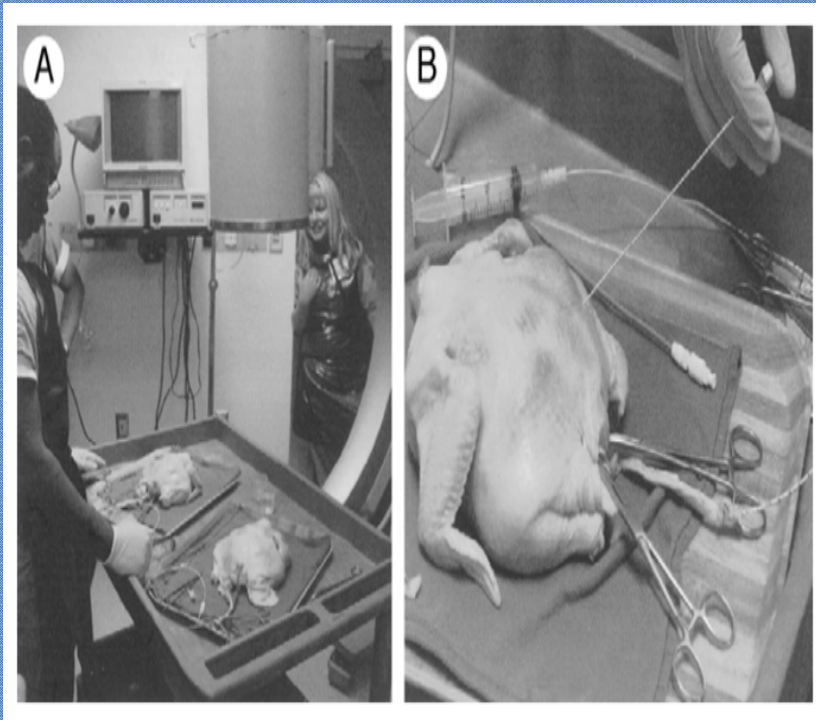


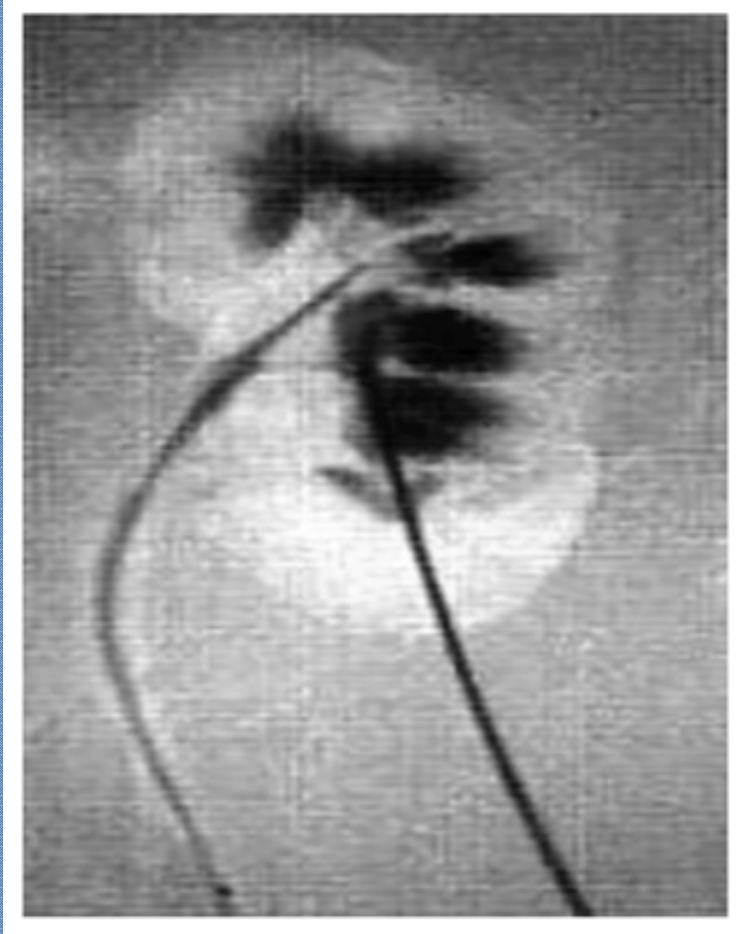


FIG. 2. Nephrostomy tract dilation. A, with fascial dilator. B, with balloon dilator.

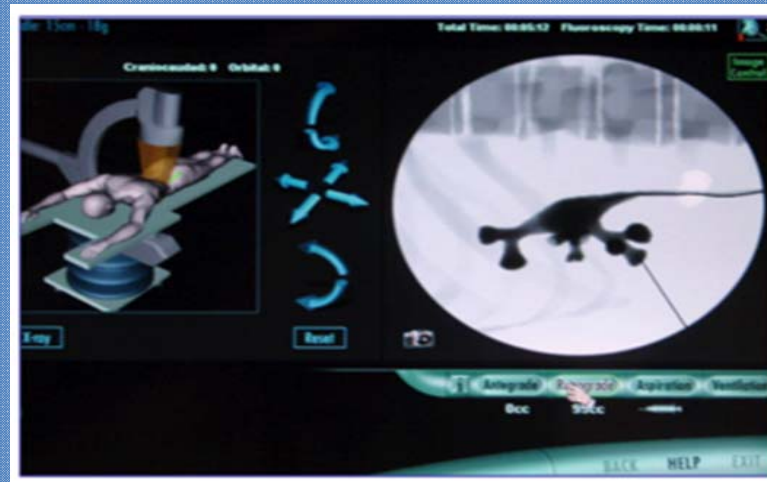
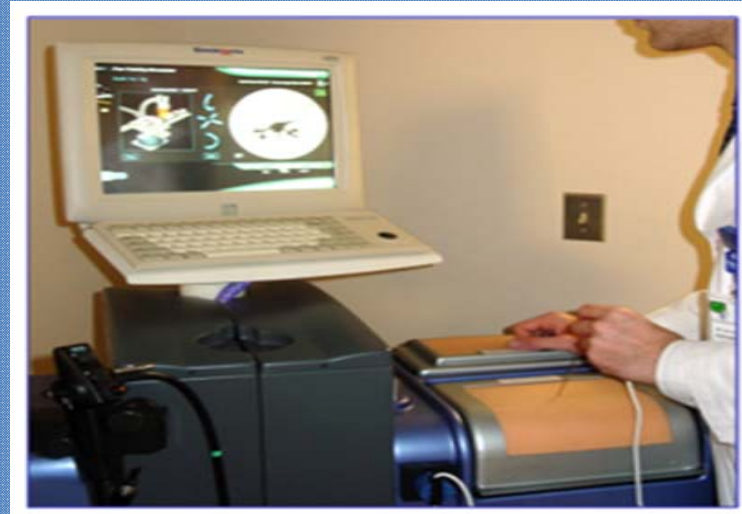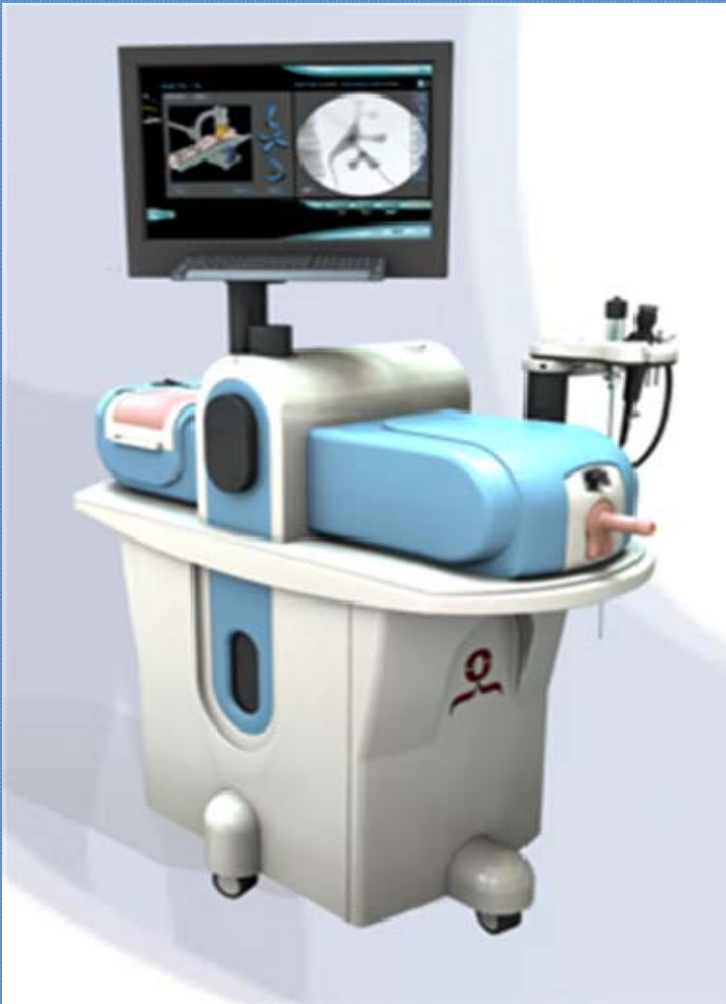Hammond L, 2004

Ex vivo hayvan modelleri-IV



Strohmaier WL, Urol Res, 2005

SİMÜLATÖR

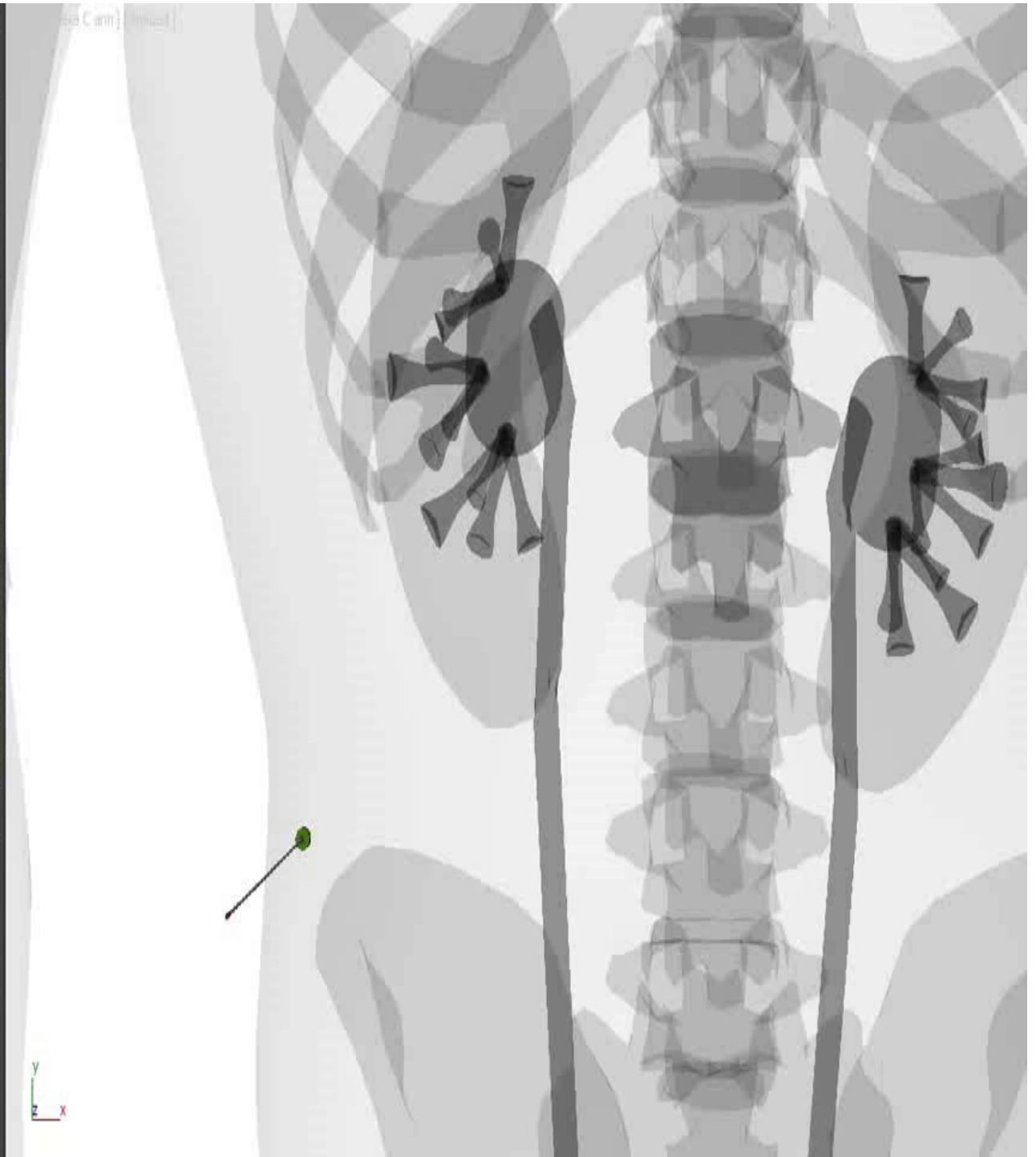
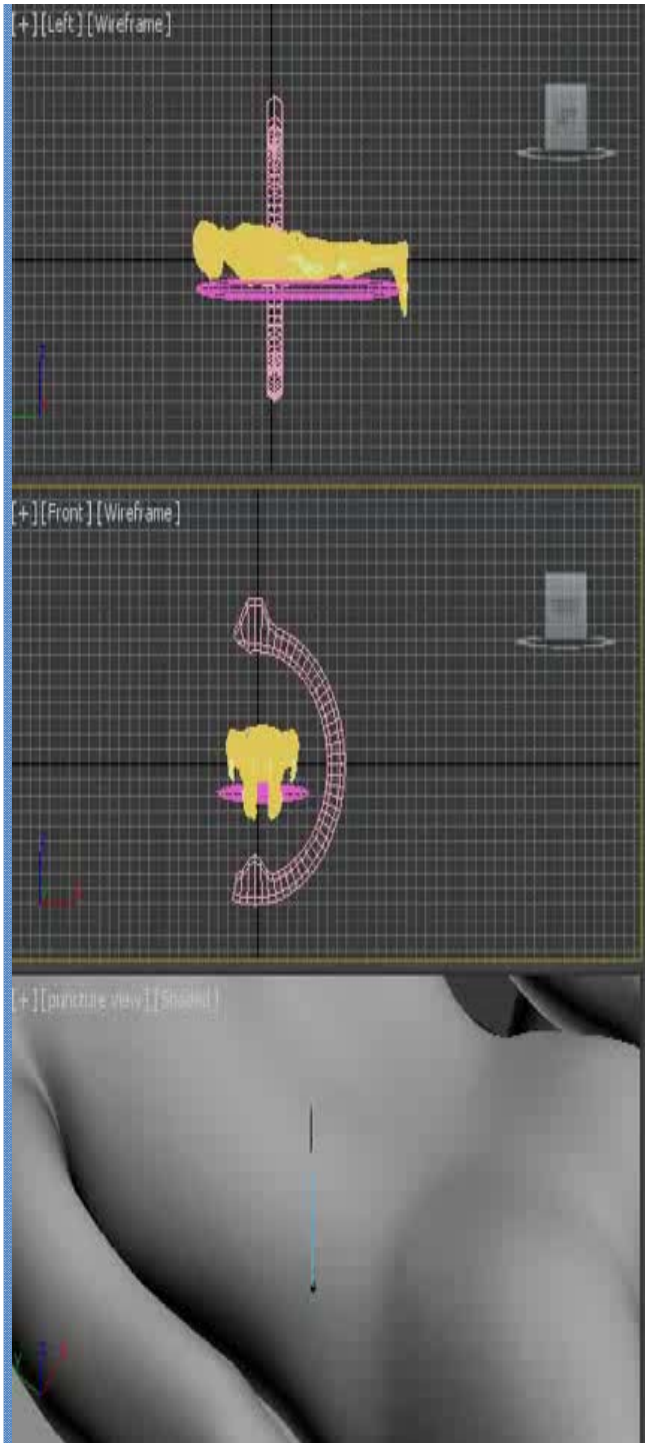


AVANTAJLARI

- Kurulumu kolay, tekrarlanabilen bir model
- Etik ve legal sorun oluşturmuyor
- Ultrason ve floroskopi
- El ve göz koordinasyonunu sağlamada
- Böbreğe ilk giriş öğrenmede iyi bir model
- Çeşitli senaryolar

DEZAVANTAJLARI

- B6breęin solunumla hareketlerini taklit edemiyor
- Komşu organları barındırmıyor
- Komplikasyonu yok
- PAHALI



ÜROLOJİ & 3D PRINT

Rapid Communication

Physical Models of Renal Malignancies Using Standard Cross-sectional Imaging and 3-Dimensional Printers: A Pilot Study

Jonathan L. Silberstein, Michael M. Maddox, Phillip Dorsey, Allison Feibus, Raju Thomas, and Benjamin R. Lee

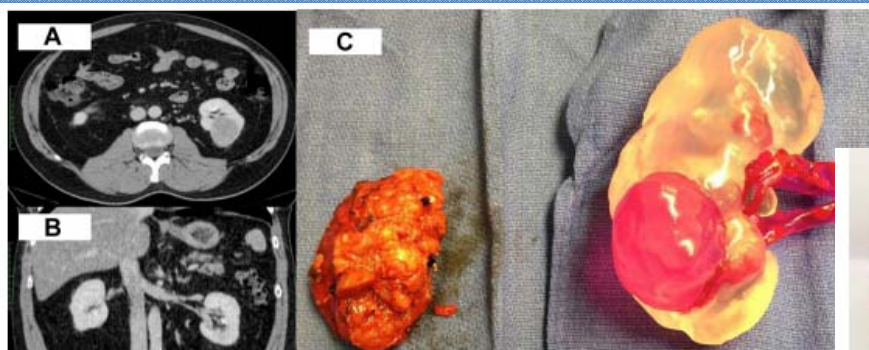
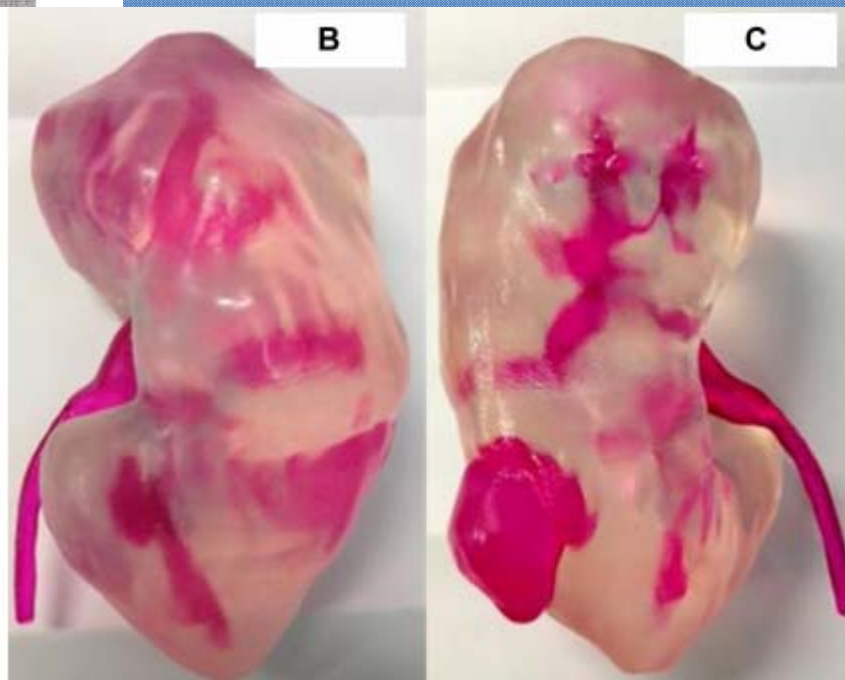


Figure 2. (A,B) Select transverse and sagittal CT images of a 57-year-old man (patient 3) with a left lower pole enhancing renal mass. (C) Resected left renal mass next to 3-dimensional physical model of left kidney (turn including major renal vasculature constructed from CT scan. CT, computed tomography.



Preoperative Planning of Percutaneous Nephrolithotomy Using Three-Dimensional (3D) Printed Models of Complex Kidney Stones

2015 Endourology Society Summer Student Scholarship
Summary Report

PCNL ' de 3D PRINT EĐİTİM

Asistan eđitimi (2 dűzlem- 3 dűzlem)

Giriř kaliksi iin operasyon ncesi planlama

Kalikslere gre tař dađılımı

İnfindubulum uzunluk ve darlık (Flexible URS)

Eđitmen Cerrah

Hasta – hasta yakını bilgilendirme

3D PRINT

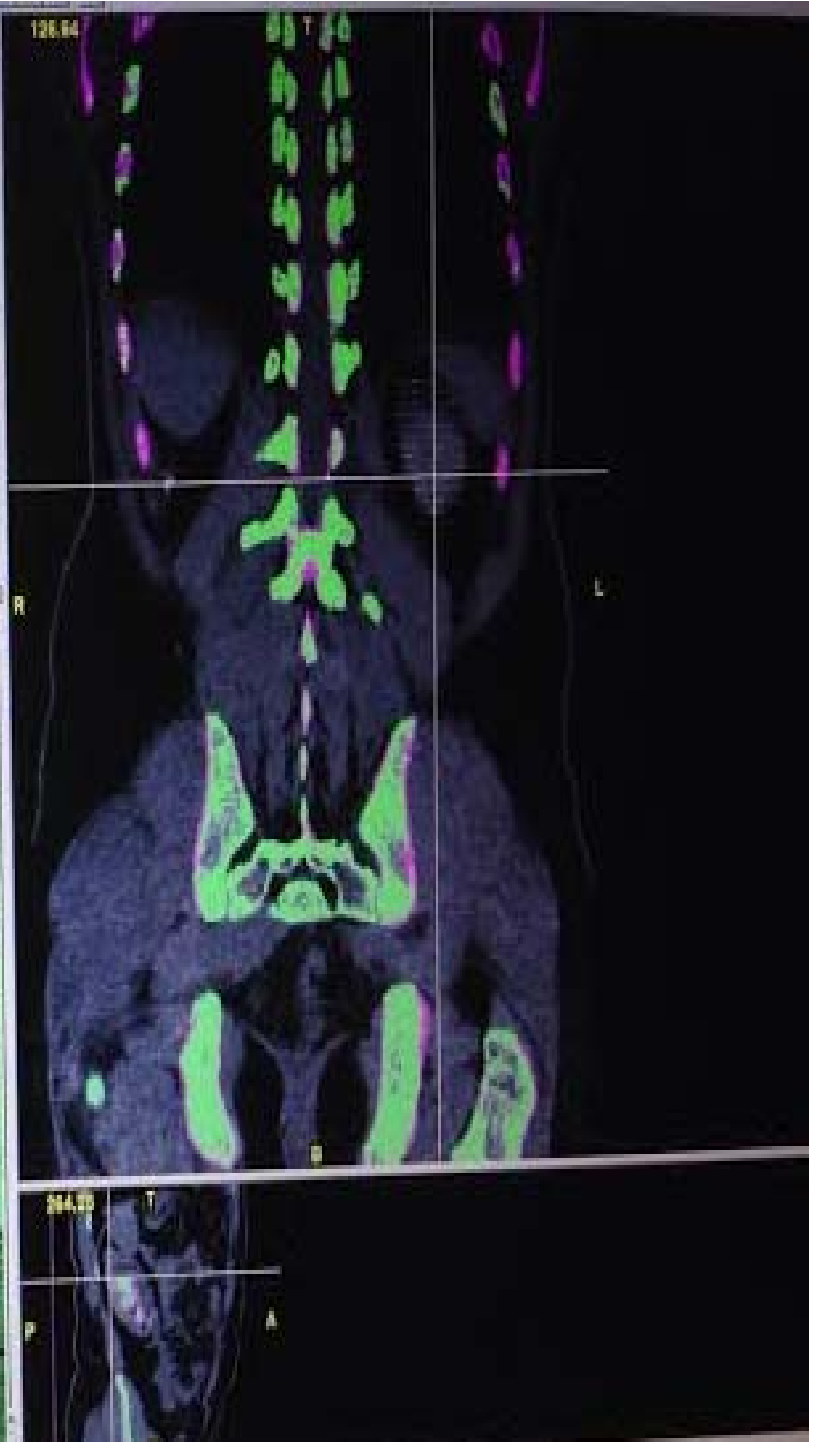
- CT ürogram Okmeydanı Eğitim ve Araştırma Hastanesi
(Centricity PACS, GE Healthcare).
- Toplayıcı sistem çıkarılması ve reformat edilmesi
Software version 16.0 (Materialise, Belgium)




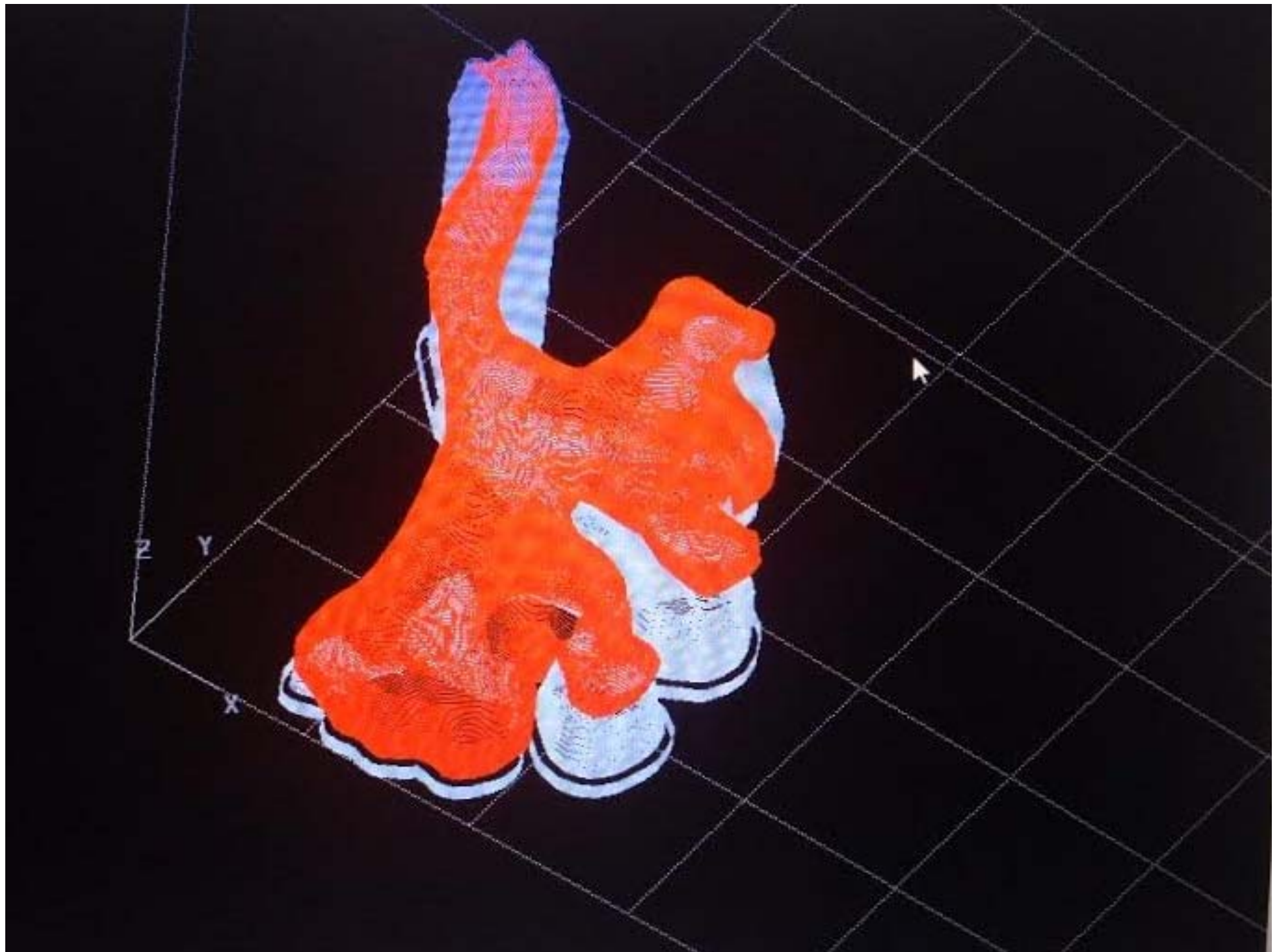
330PT

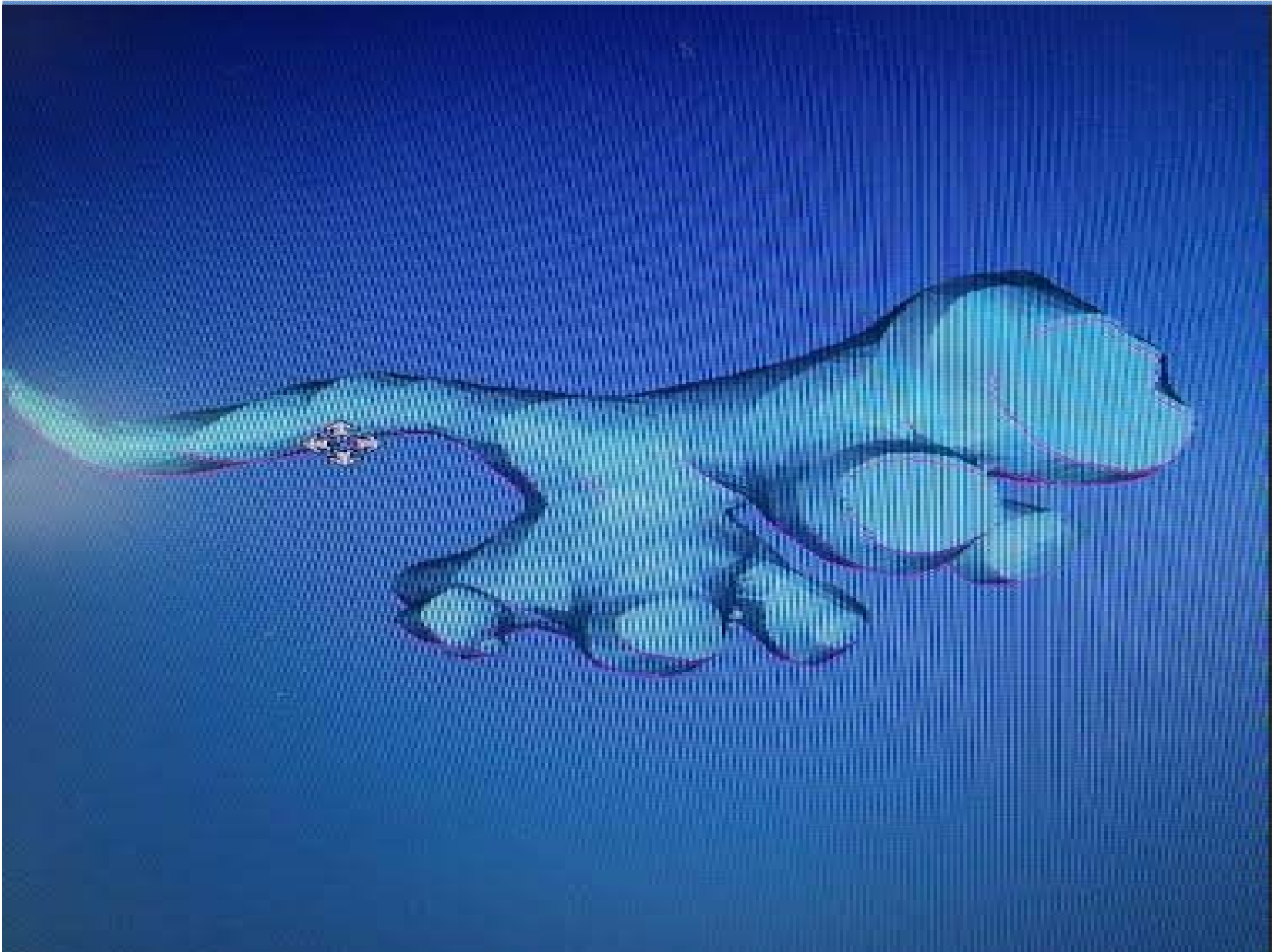
Zoom : 88.53%


WL : 128

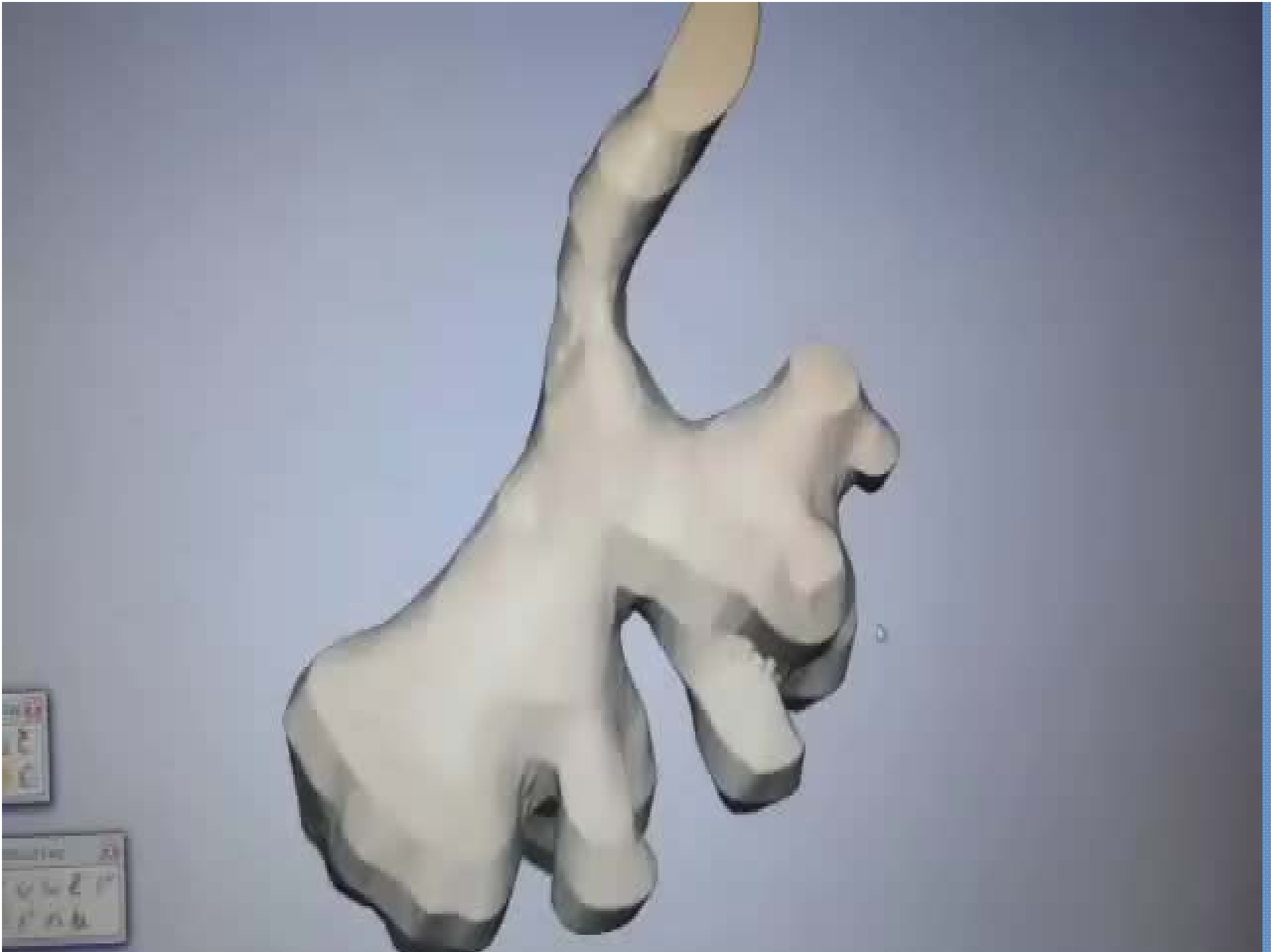








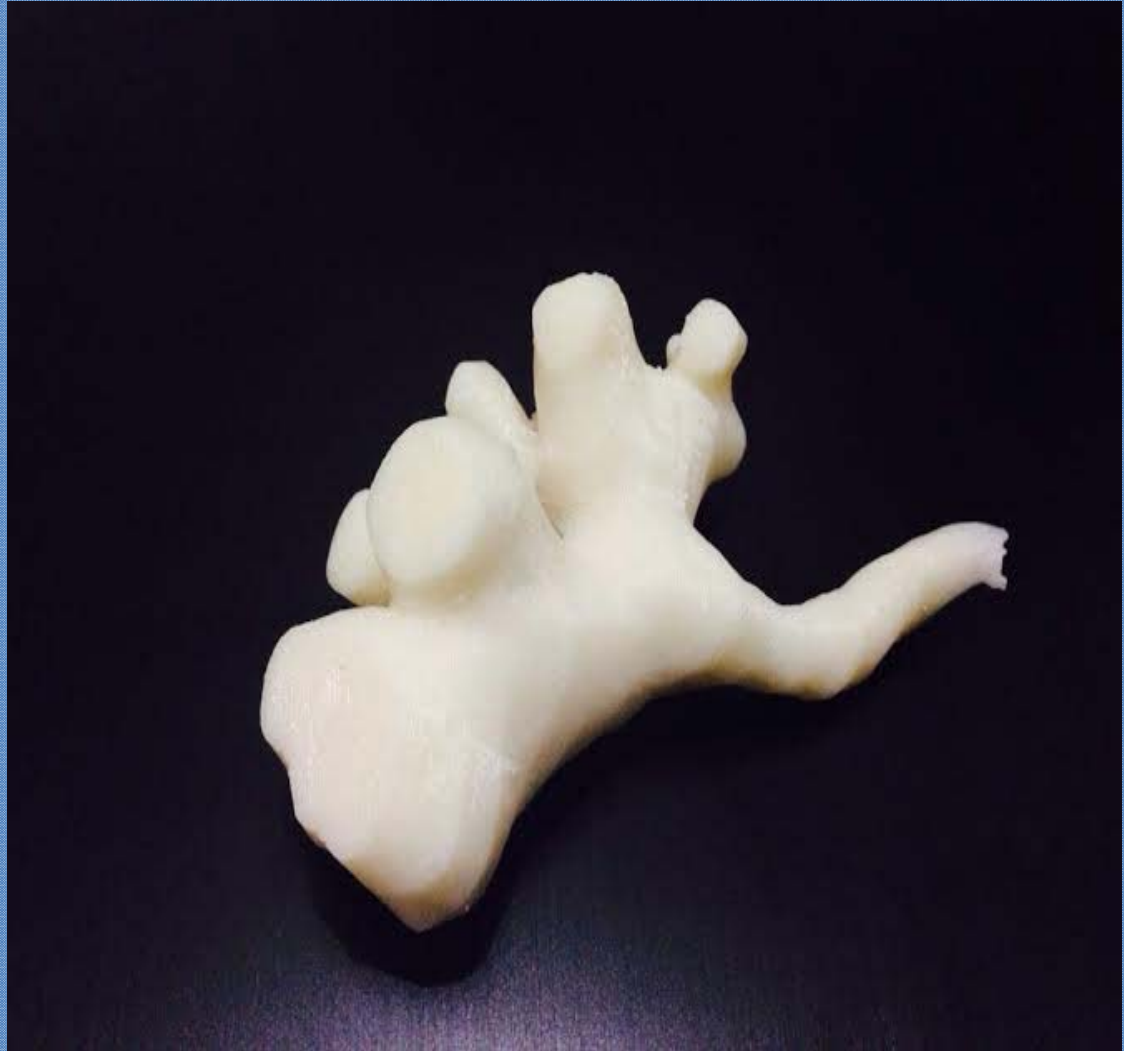
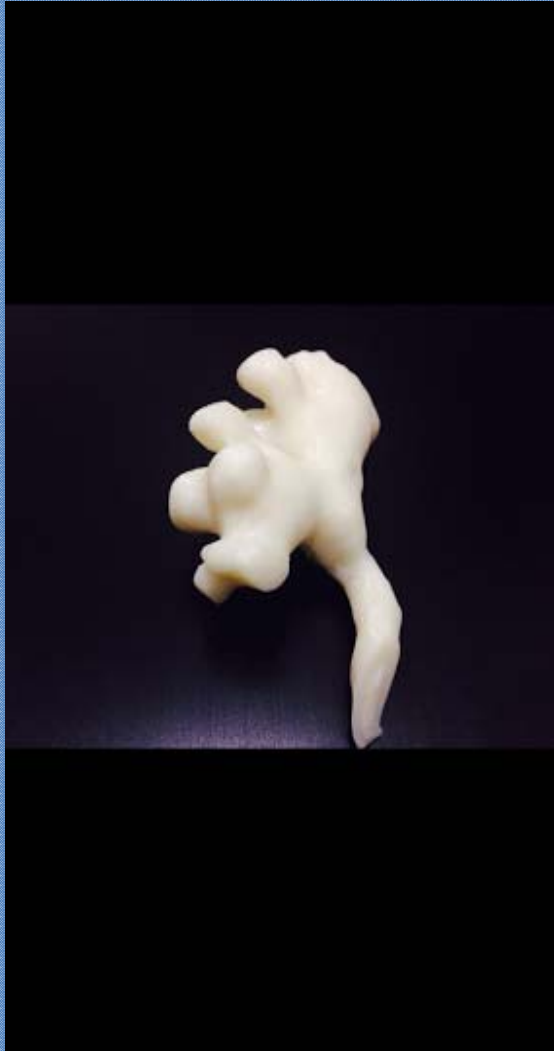


PRINT



PRINT

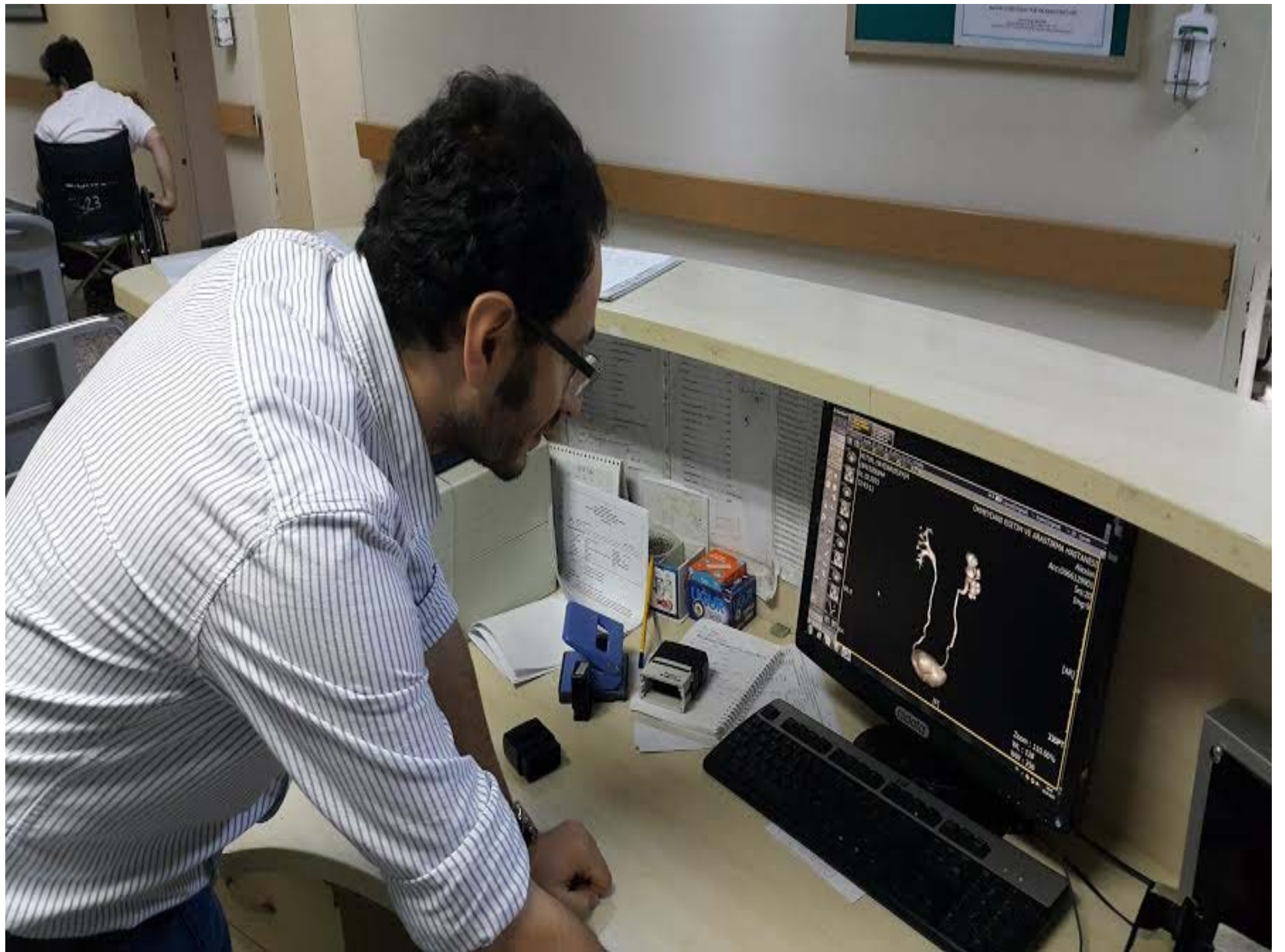

PERKÜTAN NEFROLİTOTOMİ ÖNCESİ

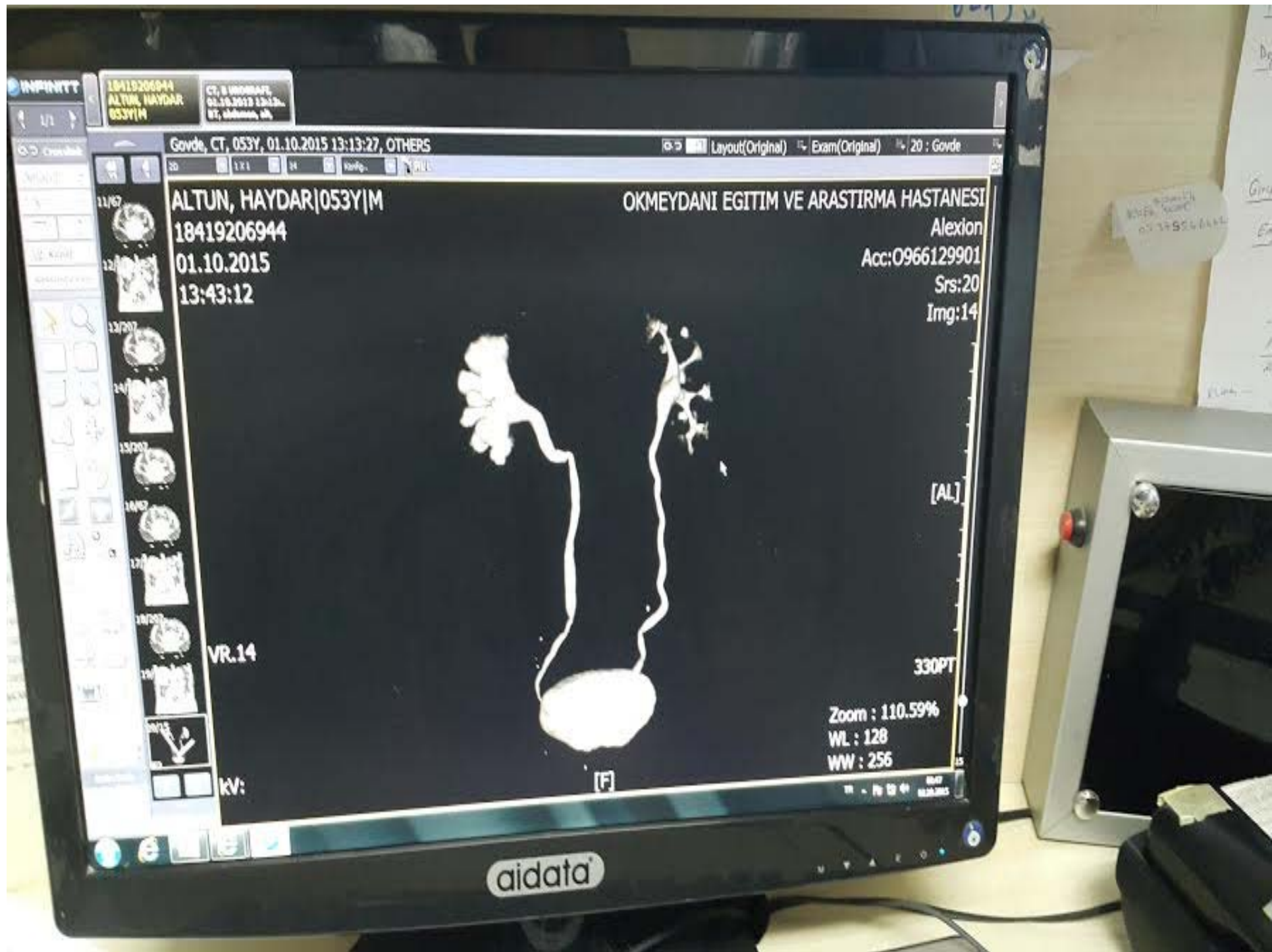
**Three-Dimensional (3D) Printed
MODEL İLE OPERASYON PLANI**

HASTA BİLGİLENDİRME









18419206944
ALTUN, HAYDAR
053YIM

CT, 8 HINDIYAT
01.10.2015 13:13:27
BT, 20mm, 20

Govde, CT, 053Y, 01.10.2015 13:13:27, OTHERS

Layout(Original) Exam(Original) 20 : Govde

ALTUN, HAYDAR|053Y|M
18419206944
01.10.2015
13:43:12

OKMEYDANI EGITIM VE ARASTIRMA HASTANESI

Alexion
Acc:0966129901
Srs:20
Img:14



- 11/07
- 12/07
- 13/07
- 14/07
- 15/07
- 16/07
- 17/07
- 18/07
- 19/07
- 20/07

VR.14

KV:

[AL]

330PT

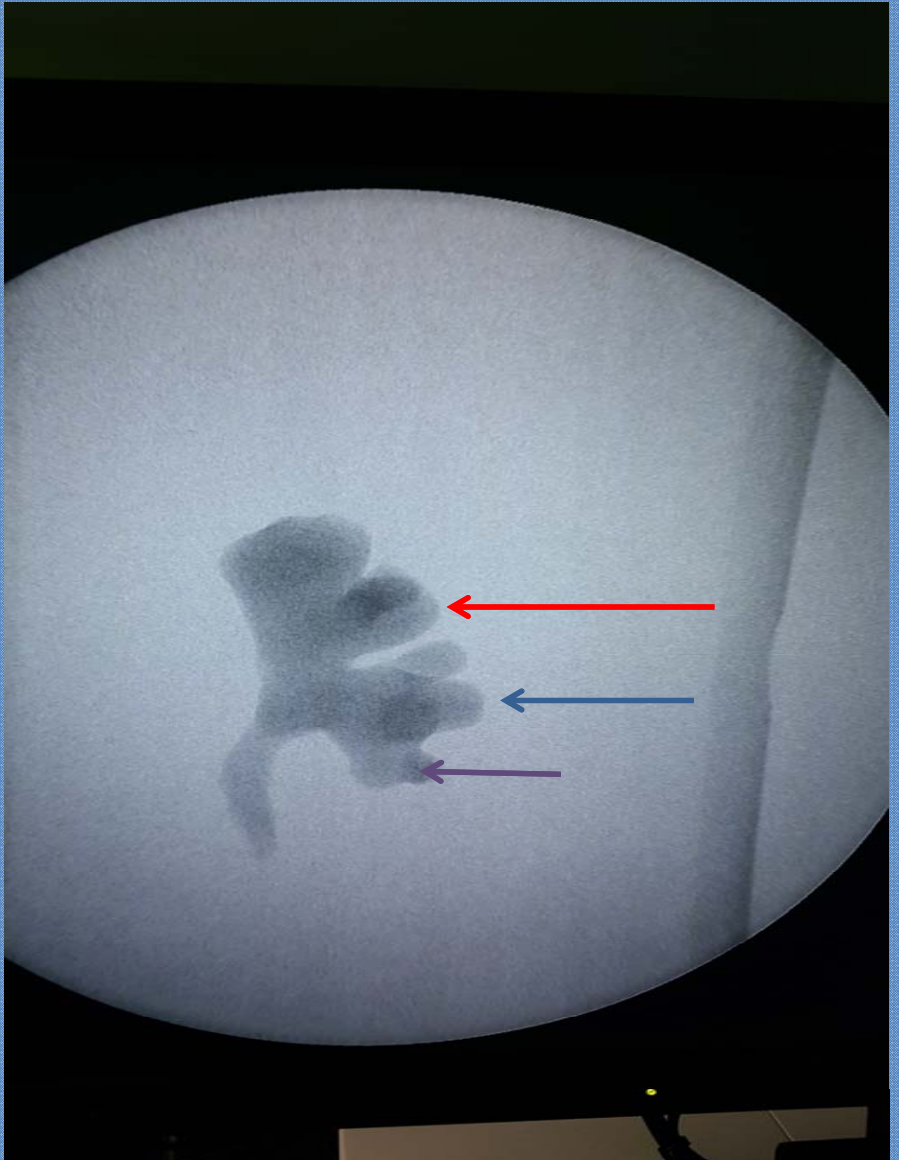
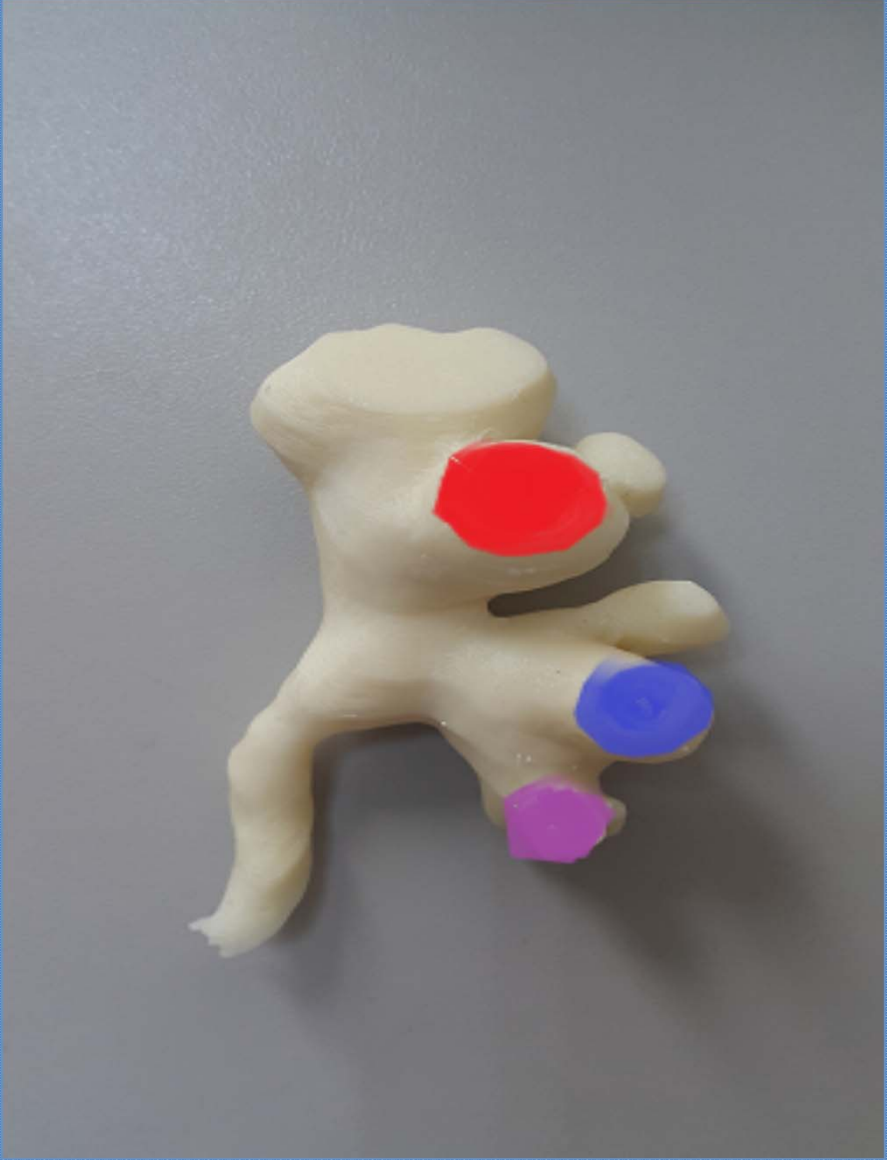Zoom : 110.59%
WL : 128
WW : 256

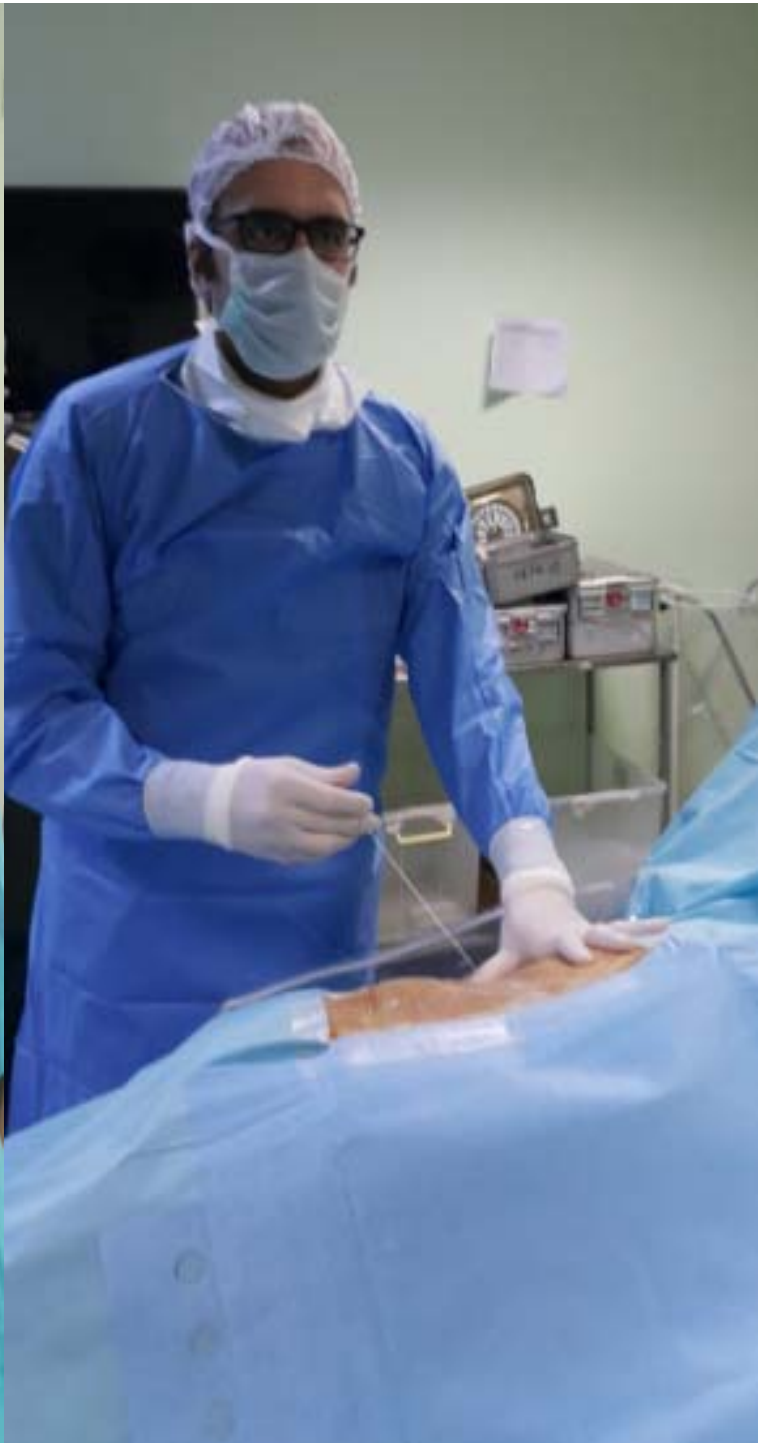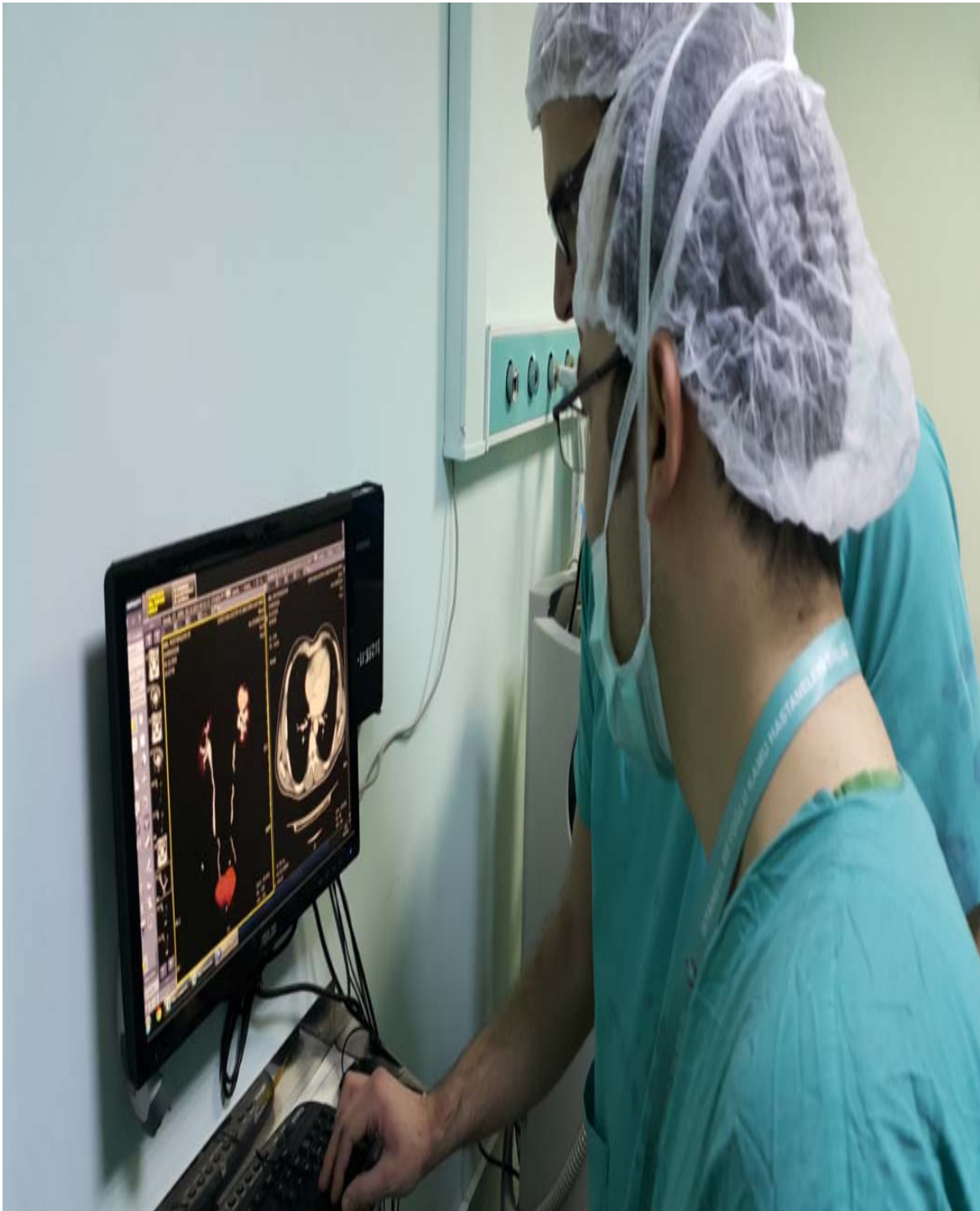aidata

07 17 55 6 61 12









LİKERT ÖLÇEĞİ

PCNL yapmada genel güven



Ameliyat planı yapabilme yeteneği



Giriş için optimum kaliksi seçme yeteneği



Taş şekli ve oryantasyonuna aşinalık



Taş lokasyonuna aşinalık



Sonuç

- Rölâtif olarak ucuz
- Anatomik uygunluk
- Non biyolojik
- Proje geliştirilmesi ile PCNL operasyonunda kolaylık

TEŞEKKÜR EDERİM ...